



# Don't loose the side branch: have a rescue plan!

Aurigemma C, Burzotta F, Trani C

INSTITUTE OF CARDIOLOGY  
CATHOLIC UNIVERSITY OF THE SACRED HEART  
ROME, ITALY



## Clinical Presentation

- ✓ Male 76 years old
- ✓ Cardiovascular Risk Factor: Hypertension, Hypercholesterolemia
- ✓ History of previous PCI on left anterior descending coronary artery
- ✓ Admitted to our hospital because of ischemia-induced exercise stress test

tobi2015

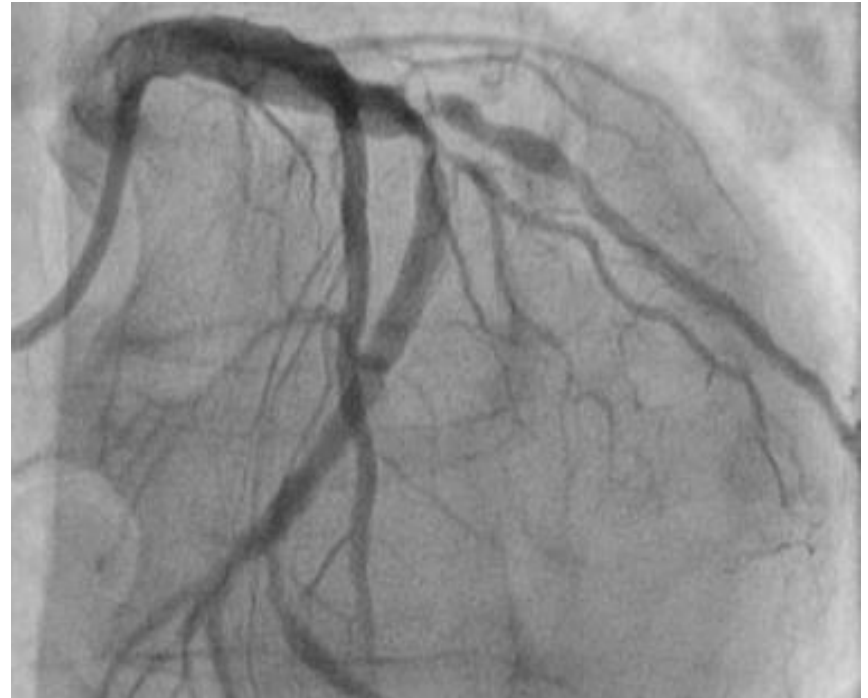
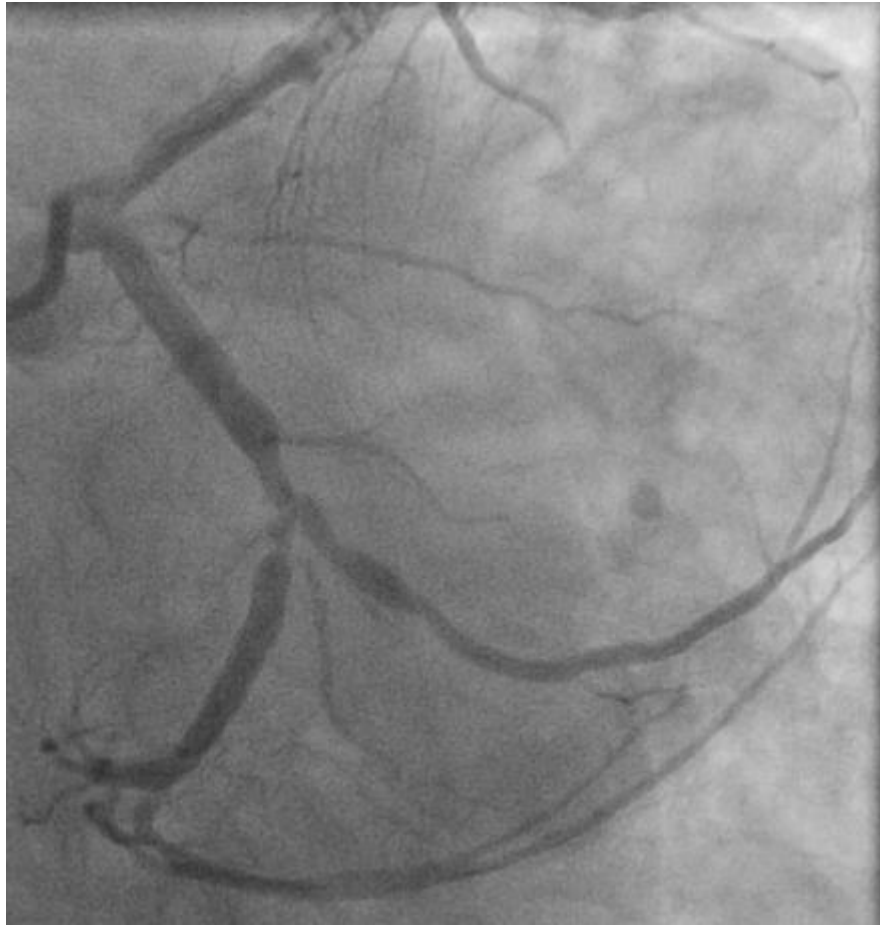October 1-2



2005-2015

Venice/Mestre

# Coronary Angiography



tobi2015


October 1-2



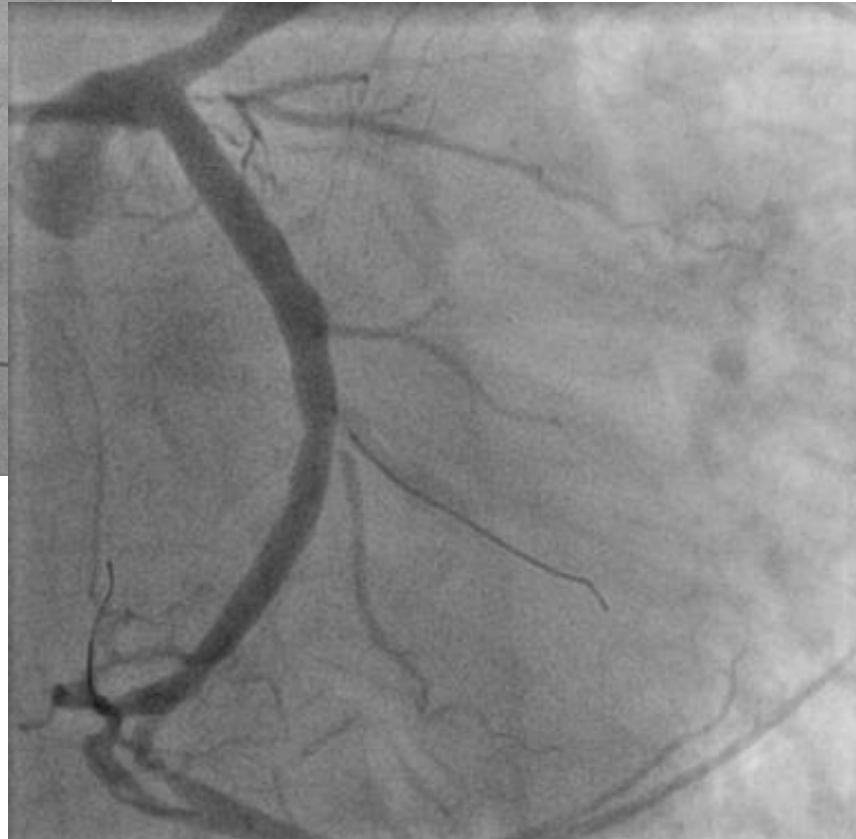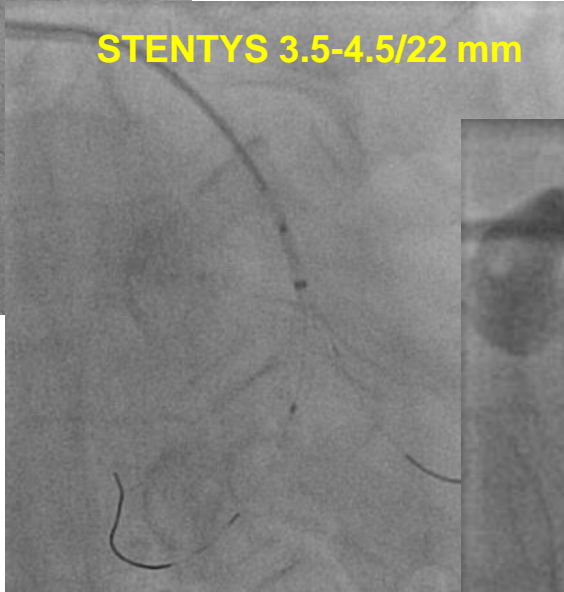
Venice/Mestre

# Coronary Angioplasty

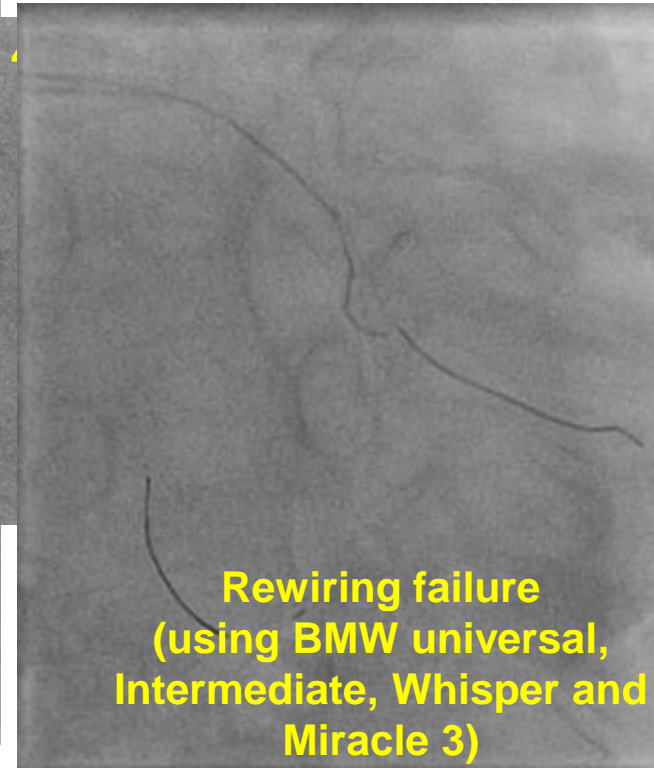
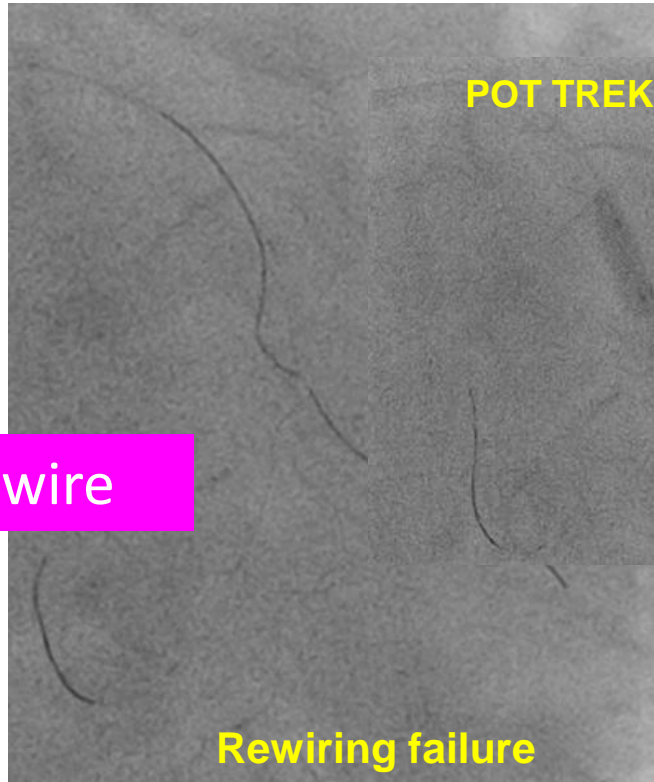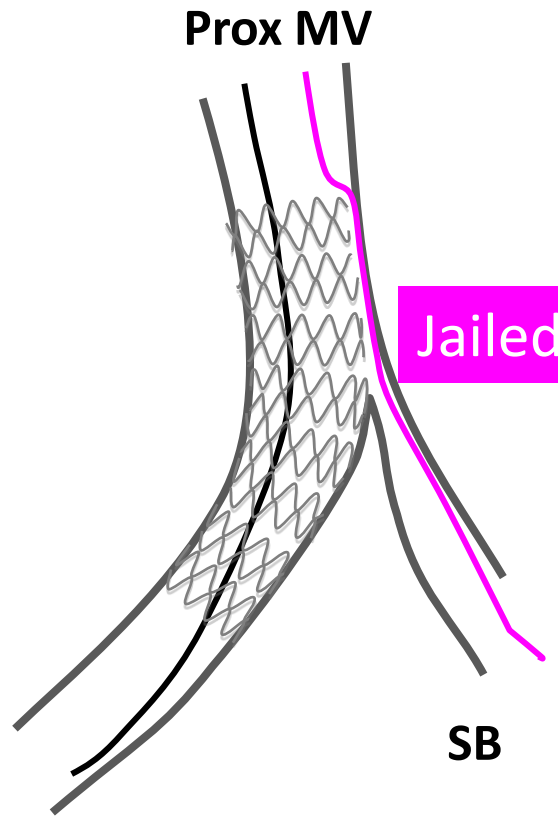
Pre-dilatation Hiryu 3.5/15 mm



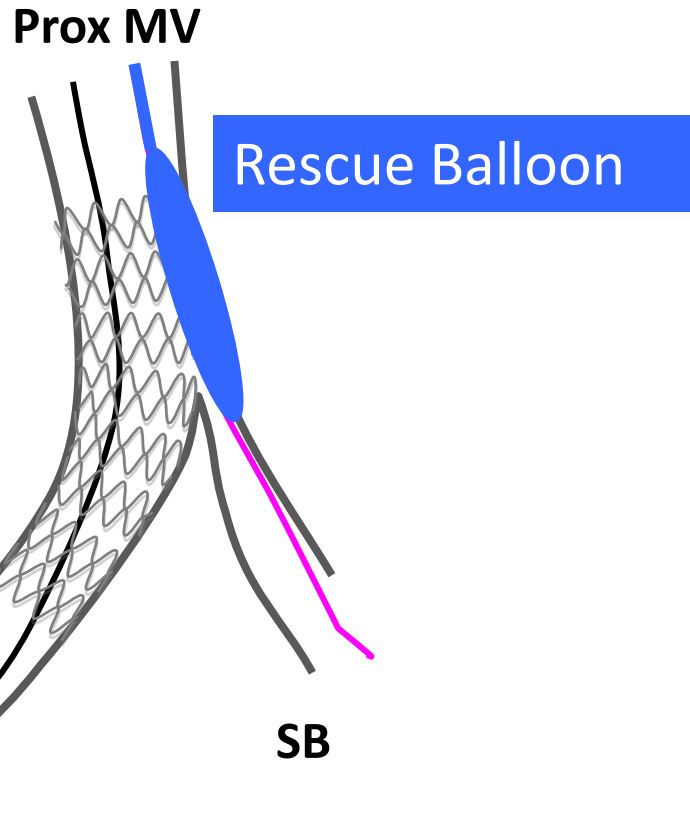
STENTYS 3.5-4.5/22 mm



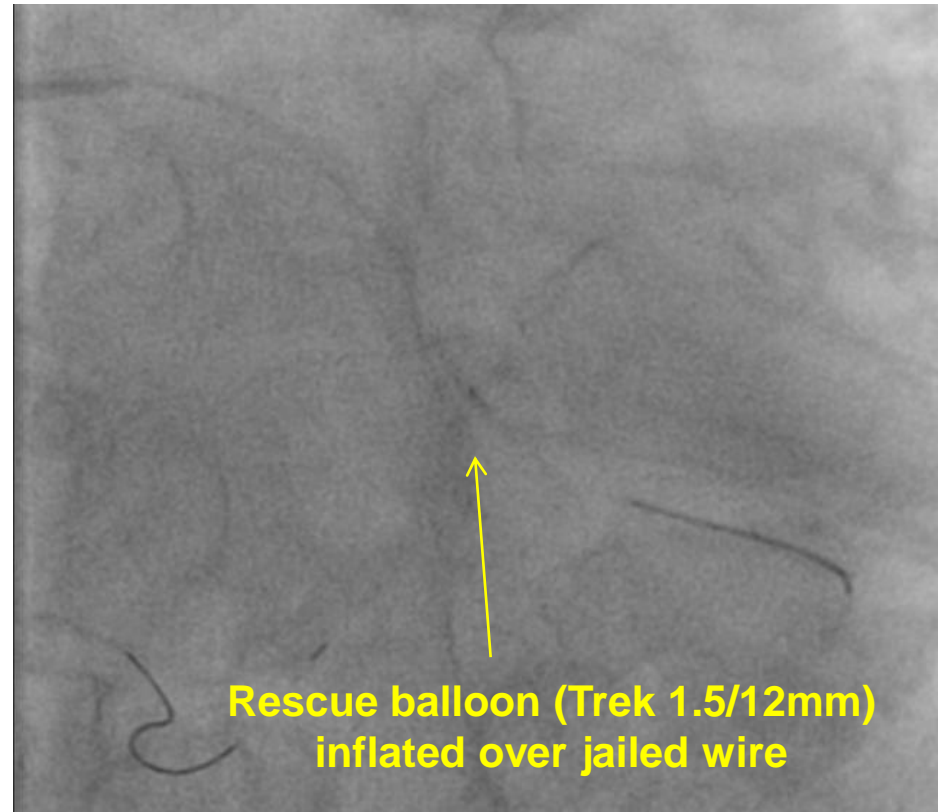
# Coronary Angioplasty



# The rescue plan....

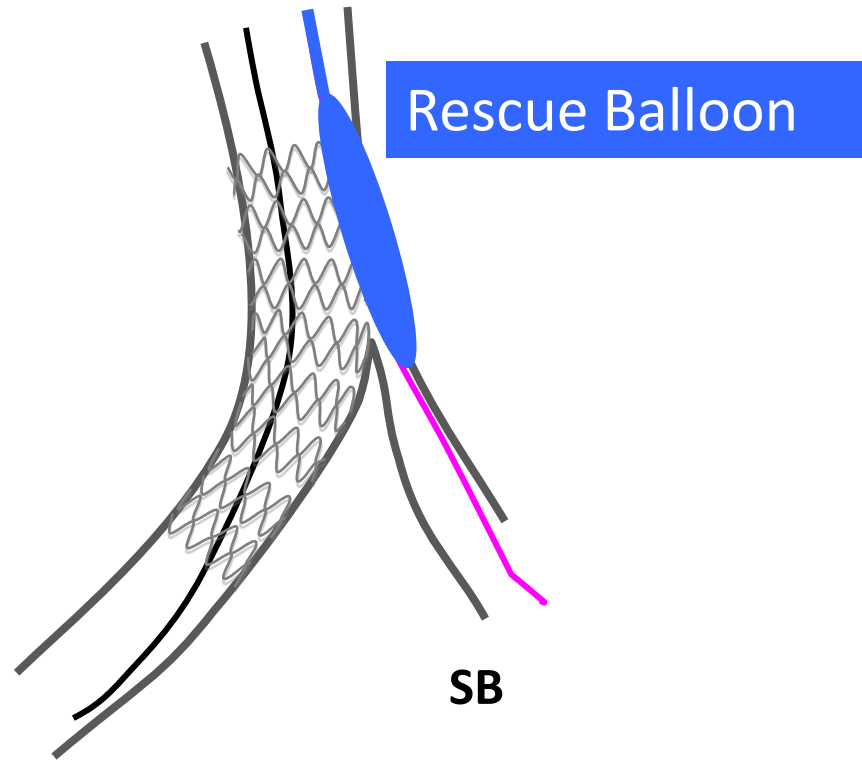


Dist MV

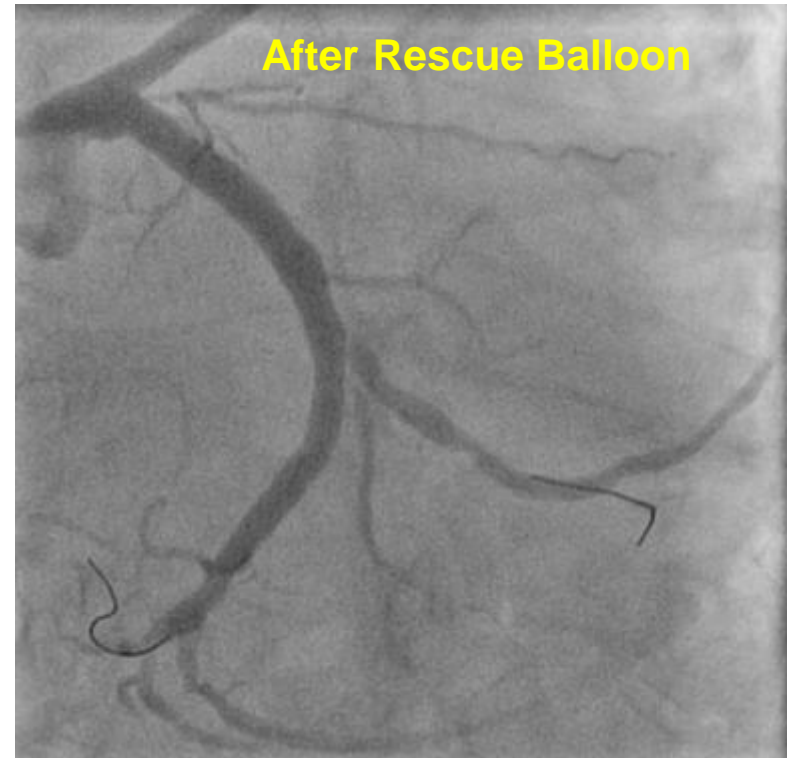


# The rescue plan....

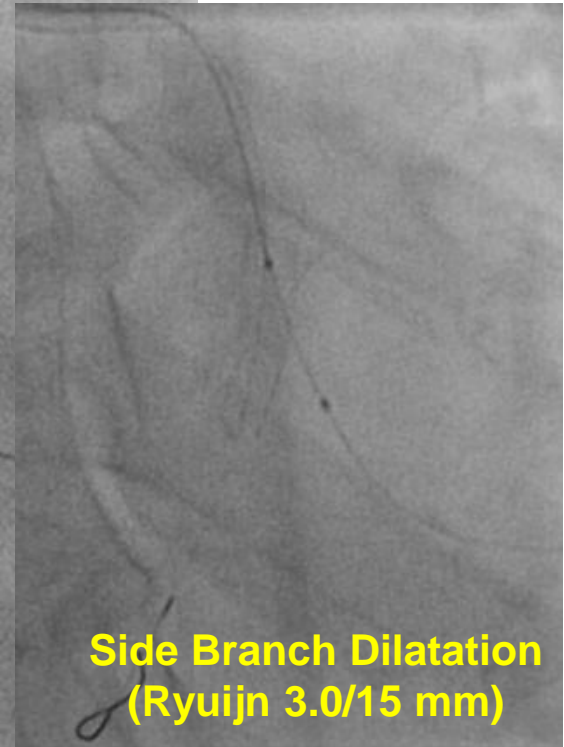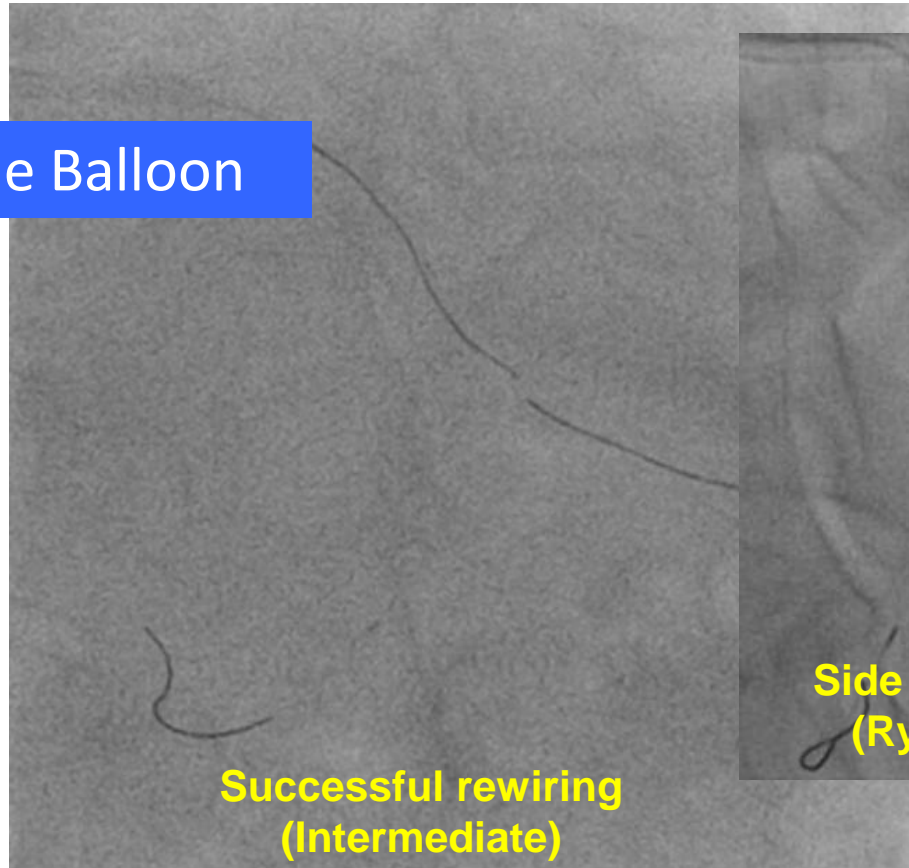
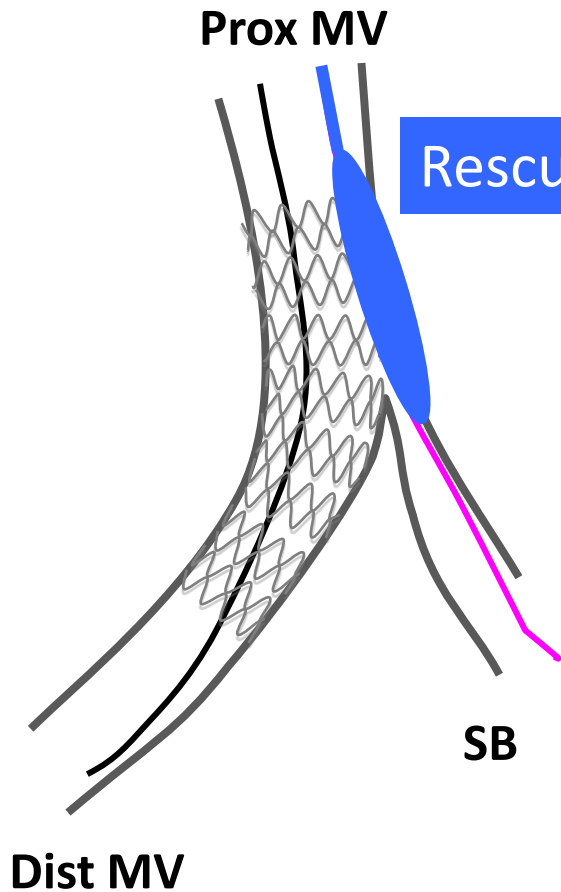
Prox MV



Dist MV

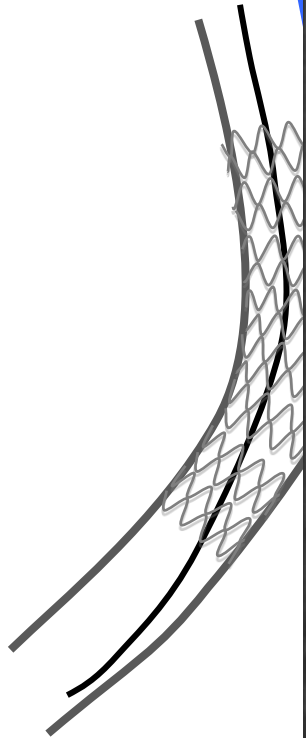


# The rescue plan....



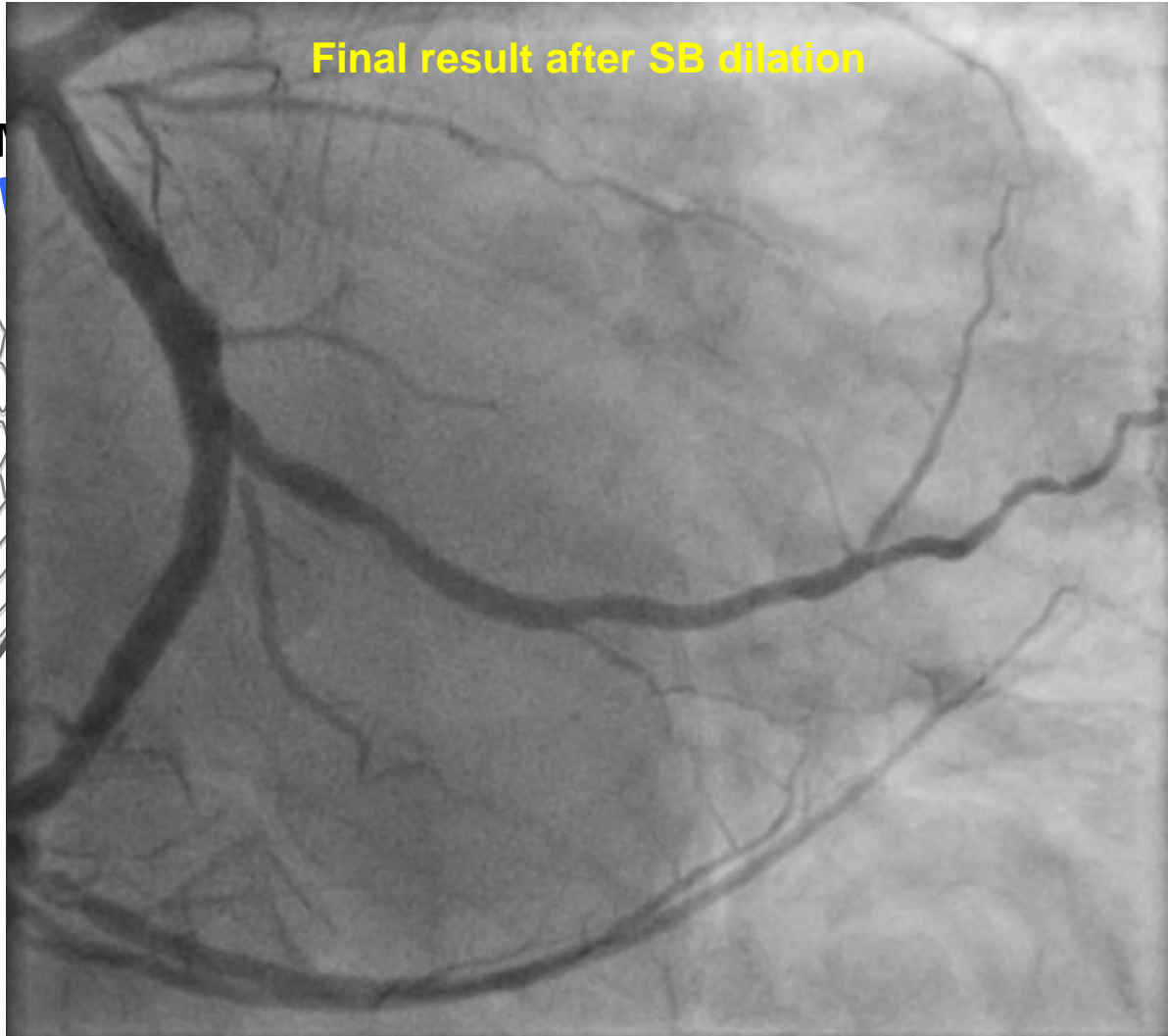


Prox M

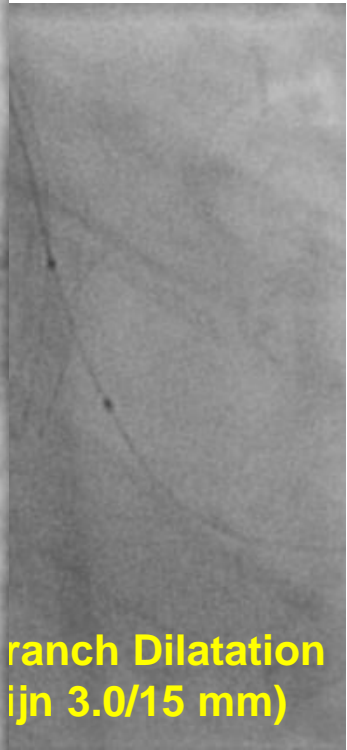


Dist MV

Final result after SB dilation



Branch Dilatation  
(ijn 3.0/15 mm)



tobi2015 October 1-2



Venice/Mestre

## DON'T LOOSE YOUR SIDE BRANCH !

- ✓ Provisional is the gold standard approach for bifurcation stenting but abrupt side branch (SB) occlusion after main vessel (MV) stent implantation is a major limitation
- ✓ In case of abrupt closure of a significant SB and rewiring failure, the jailed wire may be used to advance a small balloon (RESCUE JAILED BALLOON TECHNIQUE) in order to restore SB flow
- ✓ The RESCUE JAILED BALLOON TECHNIQUE may increase the safety of provisional stenting procedure in complex patients